

Case Report

Treatment of Class II Maxillary Retrusion Case Using Miniscrew (Nonextraction Treatment of Adolescent Patient)

Fulya Ozdemir, DDS, PhD;¹ Volkan Osman Uyar, DDS, PhD;² Feyza Ulkur, DDS, PhD³

ABSTRACT

Objective: This case report describes the protocol employed in the treatment of a patient with Class II subdivision malocclusion, with sagittal, transverse, and occlusal disharmonies.

Materials and Methods: Treatment included the expansion of the maxilla with a banded Hyrax appliance over a period of 14 days. After a retention period, the device was removed and a stainless steel transpalatal arch was attached. The maxillary arch was bonded with MBT prescription brackets, and distalization of the left maxillary first molar commenced on a 0.016 × 0.022-inch stainless steel archwire supported by a miniscrew for indirect anchorage. After 4.7 mm of molar distalization, a Nance appliance with a bite plane was placed, and the mandibular arch was bonded to continue treatment, which lasted 18 months. Mandibular and maxillary fixed retainers were placed at the end of active treatment.

Results: Pretreatment and posttreatment records showed that vertical and sagittal skeletal cephalometric findings were stable.

Conclusion: A nonextraction and miniscrew anchorage approach for distalization is an effective treatment option for dental Class II correction. (*Turkish J Orthod* 2015;27:117–127)

KEY WORDS: Class II, miniscrew, distalization

INTRODUCTION

In 1899, Edward Angle described 3 classes of malocclusion based on the anteroposterior occlusal relationship of the first permanent molars. Also described was a Class II subdivision in which the molar occlusion was Class II on one side and Class I on the other.¹

The different molar relationship reflects an asymmetry in either one or both of the dental arches, typically due to a loss of space when one primary second molar has been prematurely lost. Alternatively, an asymmetric discrepancy of the jaw or dentition could be present.² When a maxillary molar is occlusally loaded, the induced stresses are transferred predominantly through the infrazygomatic crest.³ If, however, the molars are mesially displaced, a large part of the bite force is transferred through the anterior part of the maxilla, resulting in compression loading of the buccal bone.⁴

Treatment choices to manage a Class II subdivision malocclusion could involve extractions, a nonextraction approach, or surgery depending on the nature and extent of the problem. A nonextraction approach often requires distal movement of maxillary teeth in order to achieve a Class I molar and canine relationship. Distalization can be achieved with the aid of an extraoral appliance, an intraoral molar distalizer, a fixed functional appliance, elastics, or the use of a miniscrew. Because of problems with patient compliance, clinicians often use appliances that need minimal patient cooperation. Therefore, intraoral distalization appliances have been introduced to reduce patient compliance and apply continuous forces. While these appliances are designed to minimize anchorage loss, flaring of the anterior teeth and an increased overjet often

Corresponding author: Yeditepe University, Bağdat Cad. No: 238 Göztepe, Istanbul, Turkey. Tel: 02163636044/6406 E-mail: feyza.ulkur@yeditepe.edu.tr, feyzafeyza@hotmail.com

To cite this article: Ozdemir F, Uyar VO, Ulkur F. Treatment of Class II maxillary retrusion case using miniscrew (nonextraction treatment of adolescent patient). *Turkish J Orthod*. 2015;27;118–128. (DOI: <http://dx.doi.org/10.13076/TJO-D-14-00023>)

Date Submitted: August 2014. Date Accepted: November 2014. Copyright 2015 by Turkish Orthodontic Society

¹Professor, Yeditepe University, Faculty of Dentistry, Department of Orthodontics, Istanbul, Turkey

²Private practice, Istanbul, Turkey

³Assistant Professor, Yeditepe University, Faculty of Dentistry, Department of Orthodontics, Istanbul, Turkey

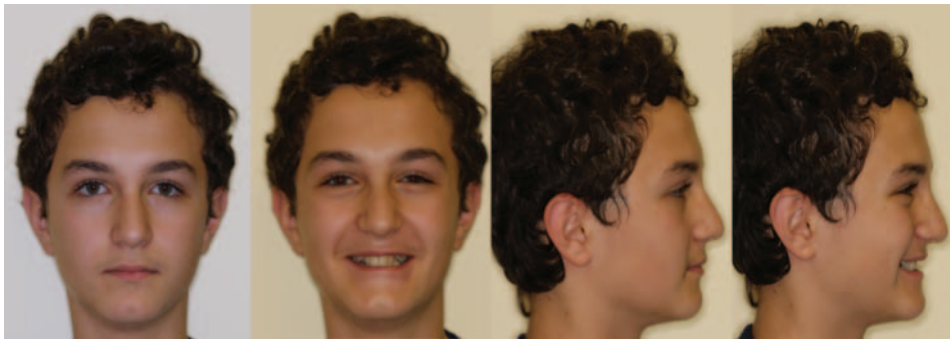

Figure 1. Pretreatment extraoral photographs of the patient.

occur. Moreover, these appliances have disadvantages related to laboratory time and expense. In addition, as posterior teeth distalize, mandibular facial height may increase due to an induced clockwise mandibular rotation.⁵ Placing a miniscrew in the buccal interradicular cortical bone and using elastics to distalize the arch is a simple and effective approach that eliminates additional connectors and has predictable and controlled outcomes.

The objective of the present article is to present the nonextraction treatment of a patient presenting with maxillary sagittal and transverse deficiency and a dental Class II relationship.

DIAGNOSIS AND ETIOLOGY

A 13-year 9-month-old boy was referred to the Orthodontic Clinic with a chief complaint of anterior crowding. The patient also reported a concern about prominent maxillary canines. The medical history of the patient revealed breathing problems during early childhood.

A soft tissue assessment in the frontal view showed a symmetric face with well-balanced vertical proportions. There was a low asymmetric smile line, thin lips, and no tooth display when at rest. A profile assessment indicated that the patient had competent lips, both of which were behind Steiner's (S) and Rickett's (E) lines. There were no signs or symptoms of temporomandibular dysfunction (Fig. 1).

The patient had a Class II molar relationship and a posterior crossbite on the left side. Even though there was no observable crossbite on the right side, the correction of the lingually inclined mandibular teeth would likely create a transverse discrepancy on that side as well. No functional shift of the mandible was detected. The maxillary midline was 2 mm to the right of the mandibular midline and the facial midline. The overjet was 2 mm and the overbite was 5 mm. Ten millimeters of crowding was measured in the maxil-

lary arch, and 5 mm of crowding was measured in the mandibular arch with both canines in infraocclusion. The maxillary arch was asymmetric because the left first molar was displaced 3–4 mm more forward than the right first molar. There was also a Bolton discrepancy of 1.5 mm in favor of the mandibular dentition (Fig. 2).

A panoramic radiograph showed normal root anatomy and no evident caries (Fig. 3a). A cephalometric analysis indicated reduced vertical dimensions, a skeletal Class III with slight maxillary retrognathia, retrusive incisors, and a straight profile (Table 1; Fig. 3b).

TREATMENT OBJECTIVES

The aim of the treatment was to correct the (1) transverse, (2) sagittal, and (3) occlusal problems; (4) incisal relations; (5) and maxillary midline, while addressing a Bolton discrepancy. Additionally, the aim was to (6) improve the profile and (7) smile esthetics of the patient.

TREATMENT ALTERNATIVES

The skeletal Class III status of the patient as a result of maxillary retrognathia was considered not severe enough to address with functional orthopaedic treatment or surgery. Since there was no genetic history of a large mandible, and cephalometrically, only a mild maxillary retrognathia existed, dentoalveolar correction was the treatment of choice. The patient's profile, vertical facial pattern, slight maxillary retrusion, and narrowness of the maxillary arch suggested a nonextraction approach.

TREATMENT PROGRESS

The maxilla was expanded with a banded Hyrax appliance (Dentaurum, Newtown, PA, USA). After 14 days of activation, expansion was completed, and the

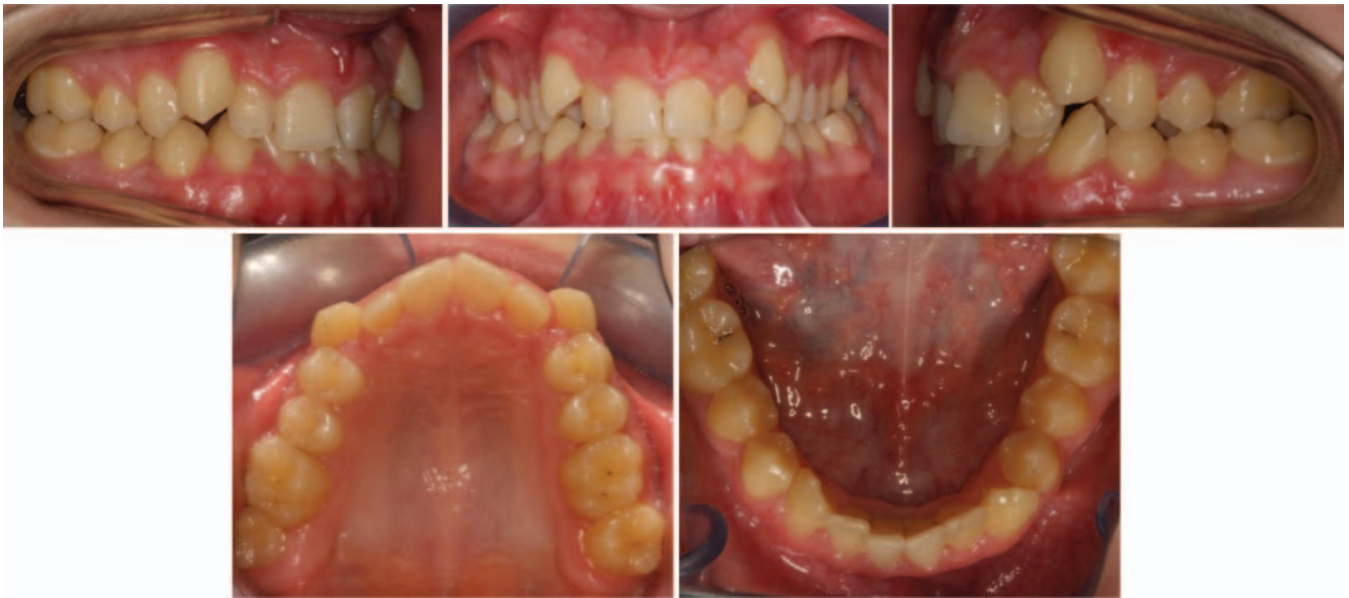

Figure 2. Pretreatment intraoral photographs of the patient.

device was left *in situ* for 3 months to provide retention (Fig. 4). Following appliance removal and the bonding of a 0.036-inch (0.91 mm) diameter stainless steel transpalatal arch, the maxillary arch was bonded with MBT prescription brackets possessing 0.022-inch slots. The arch was levelled, without engaging the left canine and after continuing alignment with 0.012, 0.016, and 0.016 × 0.016-inch nickel titanium archwires, the distalization of the left maxillary first molar

commenced on a 0.016 × 0.022-inch stainless steel archwire. A conical miniscrew (Ti-6Al-4V, Grade 5, TM Trimed, Ankara, Turkey) 1.6 mm in diameter, 8 mm in length and containing a 2-mm diameter eyelet hole in its head to secure ligature wires and elastic thread was inserted under local anaesthesia, between the maxillary second premolar and first molar teeth. The self-drilling miniscrew was placed 7 or 8 mm into the alveolar bone at an angle of 20°–30° to the long axis of

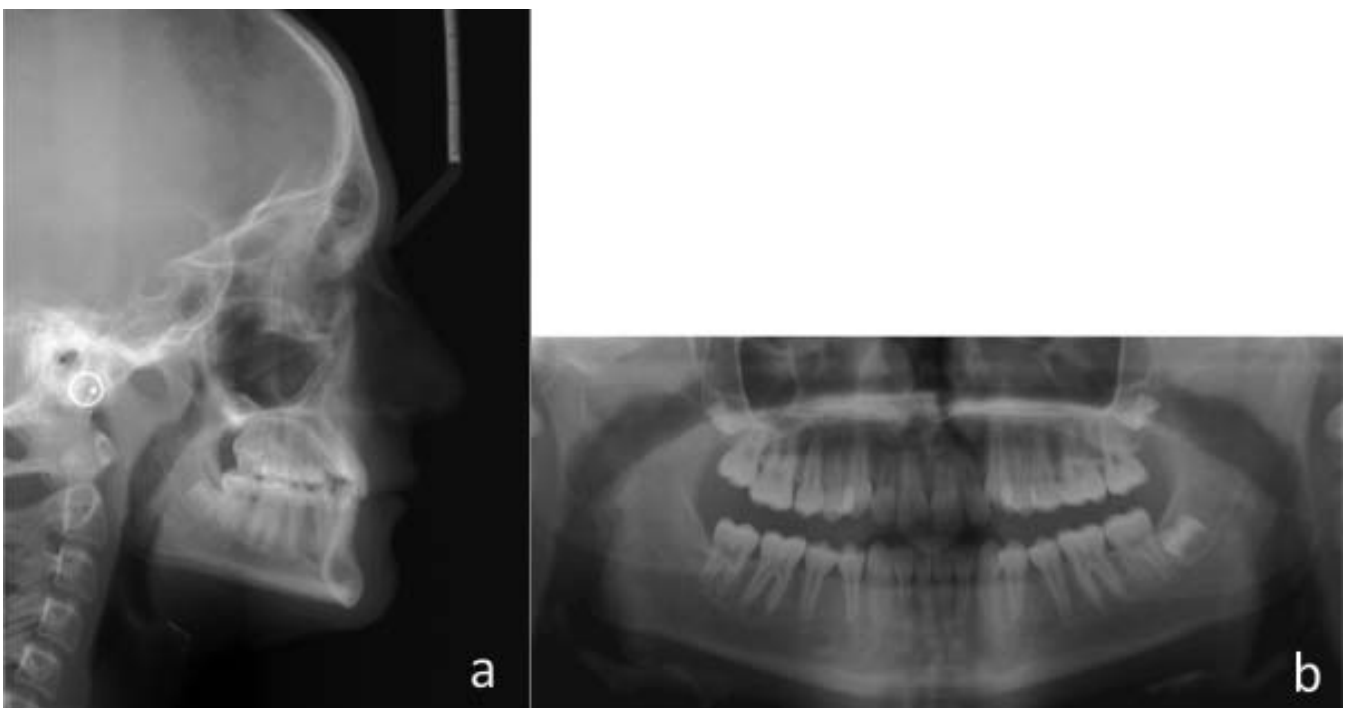


Figure 3. (a) Pretreatment panoramic x-ray. (b) Lateral cephalometric x-ray.

Table 1. Lateral cephalometric values of pretreatment, posttreatment, and 2 years after orthodontic treatment of the patient

Cephalometric Measurement	Pretreatment	Posttreatment	2 Years After Treatment
Skeletal analysis			
Vertical plane			
Go-Me-SN, degrees	28	29	29
Saddle angle, degrees	128	129	129
Articular angle, degrees,	143	146	146
Gonial angle, degrees,	116	116	116
Sum of inner angles, degrees	387	391	391
Jarabak ratio	84/124 67%	84/126 66%	84/127 66%
ANS-Me/N-Me ratio	65/124 52%	68/126 54%	68.5/127 54%
Maxillary height, degrees	62	61	61.5
Facial axis, degrees	87	88	88
S-Ar/ramus ratio	38/48 79%	38/51 74%	38/51 74%
Gonial ratio	47/66 71%	48/67 72%	48/67 72%
FMA, degrees	19	20	20
Y axis, degrees	61	62	63
Occlusal plane/SN, degrees	20	19	19
Occlusal plane/mandibular plane, degrees	9	10	10
Palatal plane/SN, degrees	9.5	9	9
Palatal plane/mandibular plane, degrees	17	19	19
Anteroposterior plane			
SNA, degrees	73	75	75
SNB, degrees	74	74	74
ANB, degrees	-1	1	1
N per-P A, mm	-9	-6	-6
Maxillary depth, degrees	82	84	84
Dental analysis			
Upper incisor inclination			
I-SN, degrees	98	102	102
I-palatal plane, degrees	107	111	111
Lower incisor inclination			
IMPA, degrees	85	96	96
Holdaway ratio	1/5	3/5	3/5
I-I, degrees	149	129	129
Soft tissue analysis			
Nasolabial angle, degrees	102	101	101
Holdaway angle, degrees	7	6	6
Upper lip-E plane, mm	-5	-6	-6
Lower lip-E plane, mm	-5	-5	-5
Soft tissue convexity, degrees	168	175	175

the proximal tooth, and its head was adjusted to a level 2 mm above the mucosa⁶ (Fig. 5). In order to avoid soft tissue inflammation, the patient was instructed to brush the transmucosal portion of the miniscrew. Loading started immediately with a force of 150 g by the use of a coil spring attached between the left first premolar and molar, and by tying a ligature between the miniscrew and the first premolar. The bracket attached to the maxillary left second premolar was removed to increase the length and working range of the open coil spring. This indirect anchorage design

allowed the coil to distalize the first molar, while the bone anchor eliminated forward movement of the first premolar. After the distalization of the molar, the miniscrew was removed and replaced in a more distal position, just mesial to the second molar. The premolars were distalized against the first molar, which was fixed to the miniscrew. Following molar distalization, a Nance appliance with a bite plane was placed, and the mandibular arch was bonded in the same appointment (Fig. 6). A maxillary 0.016 × 0.022-inch stainless steel archwire with step bends to maintain

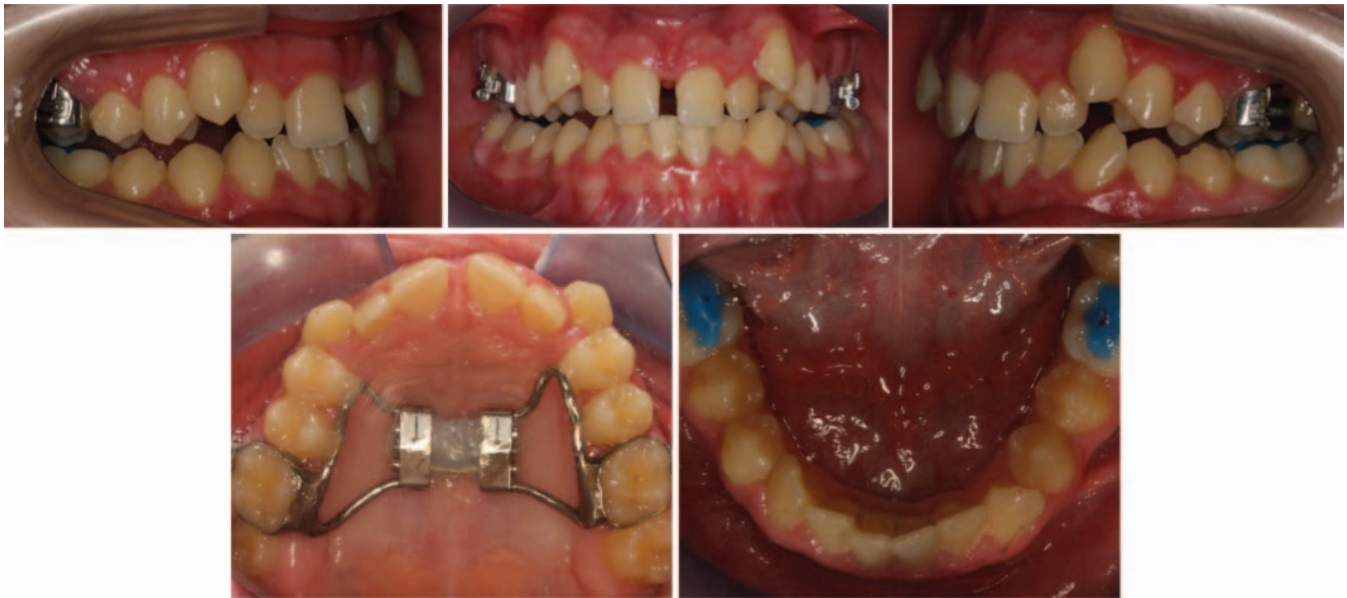

Figure 4. Intraoral photographs after banded Hyrax activation.

space for left maxillary canine was inserted. Extrusion of the canine was accomplished by a 0.012-inch nickel titanium wire inserted into the lateral incisor, canine, and first premolar brackets as an auxiliary archwire. Active treatment spanned 18 months. Mandibular and maxillary fixed retainers were provided, and posttreatment and 2-year review records showed that the occlusion remained stable.

CASE ASSESSMENT

The profile improved as evidenced by the post-treatment extraoral photographs (Fig. 7). Class I

canine and molar relationships, a normal overjet and overbite, and midline coincidence were achieved (Fig. 8). Radiographically, the tooth roots appeared well aligned (Fig. 9a). The incisors in both arches were proclined (Fig. 9b), but negligible changes were observed in the vertical dimension. While there was no change in the sagittal position of B point, A point moved forward, which may be a result of more bodily forward movement of the maxillary compared with the mandibular incisors (Table 1; Fig. 10). The cephalometric values and extraoral and intraoral photographs showed that the orthodontic treatment

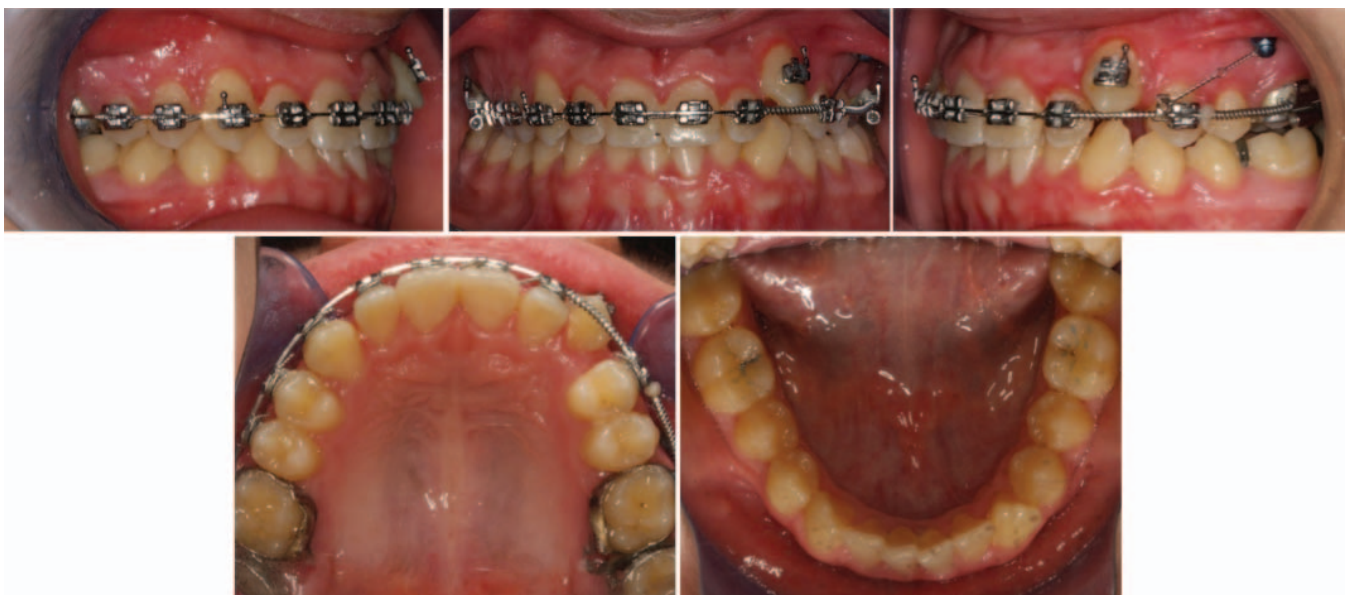

Figure 5. Intraoral photographs of screw and passive open coil insertion.

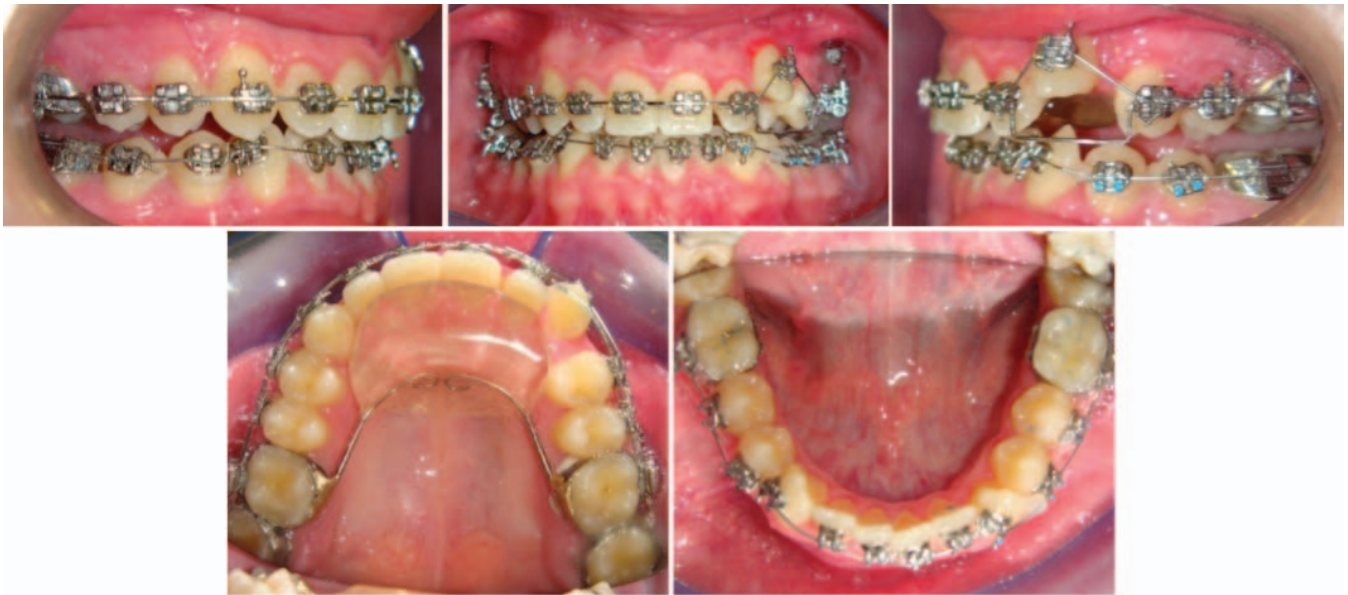

Figure 6. Nance appliance and leveling of the maxillary left canine by mini auxiliary archwire.

was stable 2 years after treatment (Table 1; Figs. 11 through 13). The extraoral images are in their original format, but appear relatively, vertically compressed in the postretention records because of the subsequent weight gained by the patient.

DISCUSSION

This case report presents the successful treatment of a patient with maxillary expansion and molar distalization with the help of a miniscrew. The posttreatment frontal photographs reveal adequate gingival display, which endorsed the nonextraction approach. In addition, the patient's straight profile in the postretention extraoral photographs reveals that the new position of the incisors supported the thin lips favorably and appropriately. It is speculated that extraction approaches might induce unfavorable dentoalveolar side effects such as tilting of the occlusal plane, molar extrusion, maxillary and man-

dibular midline deviation, and secondary skeletal changes in the frontal plane.⁷ If extractions were conducted to manage the crowding in this narrow arch, maxillary arch length would reduce and therefore increase the sagittal and transverse discrepancies that may have required surgery for correction.⁸ The expansion of the maxillary arch with a banded Hyrax appliance was the treatment of choice to help resolve the crowding and to correct the crossbite. Since extraction of a premolar from the left side could cause asymmetry, the segment was distalized. The distalization could have been accomplished using Class II elastics, but elastics on one side only would likely create an asymmetry in the mandibular arch and a cant of the occlusal plane. In the treatment of an adolescent patient, noncompliance mechanics could also be decisive in delivering an acceptable result.

When a nonextraction treatment is planned, intraoral appliances can be used to distalize the maxillary molars 1 or 2 mm per month over 4 to 5

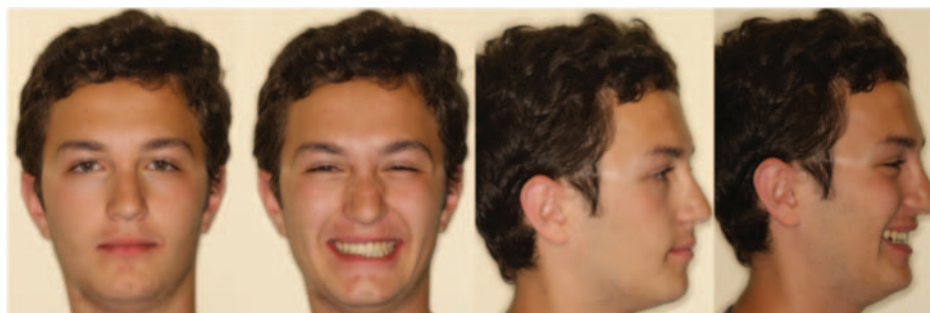

Figure 7. Extraoral photographs after orthodontic treatment.

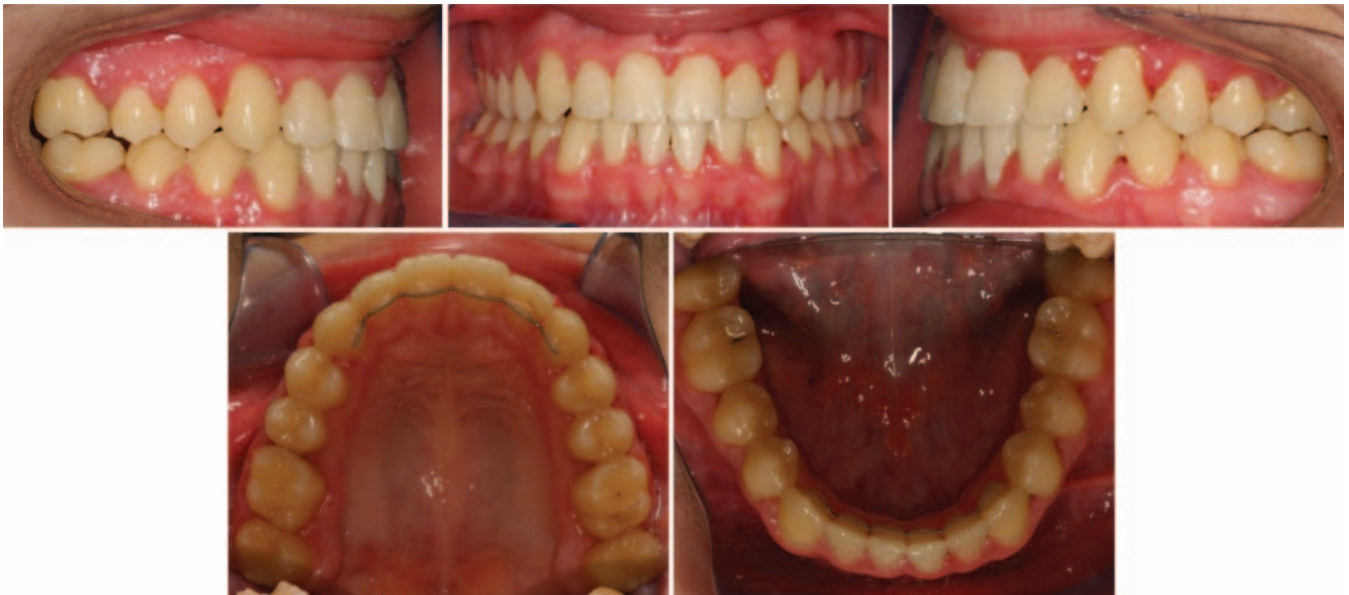

Figure 8. Posttreatment intraoral photographs, fixed retainers on maxillary and mandibular anterior teeth.

months; however, side effects like tipping and mesialization of premolars, protrusion of maxillary incisors, an increase in overjet, and a decrease in overbite should be recognised.⁹ Also, it has been reported that the presence of second molars increases treatment time and causes more tipping and more anchorage loss.¹⁰ Intermaxillary elastics or fixed functional appliances have advantages and also some disadvantages, depending on their

specific case.¹¹ In the present case report, a miniscrew was used to distalize the left segment, starting from the first molar. As a result, a negligible amount of incisor proclination and no premolar mesialization occurred during molar distalization, and no molar anchorage loss or occlusal tilting occurred during subsequent premolar distalization.

The miniscrew used in the present case was inserted in the buccal posterior region between the

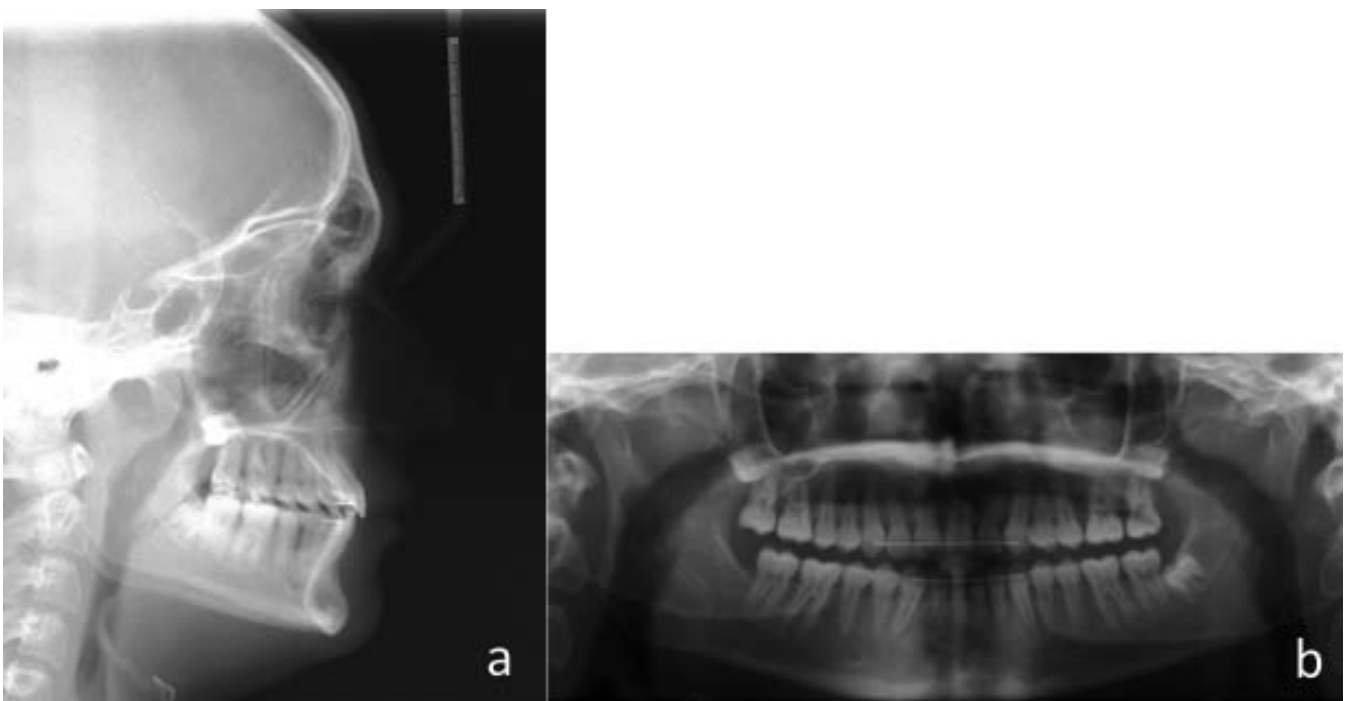


Figure 9. (a) Posttreatment panoramic x-ray. (b) Lateral cephalometric x-ray.

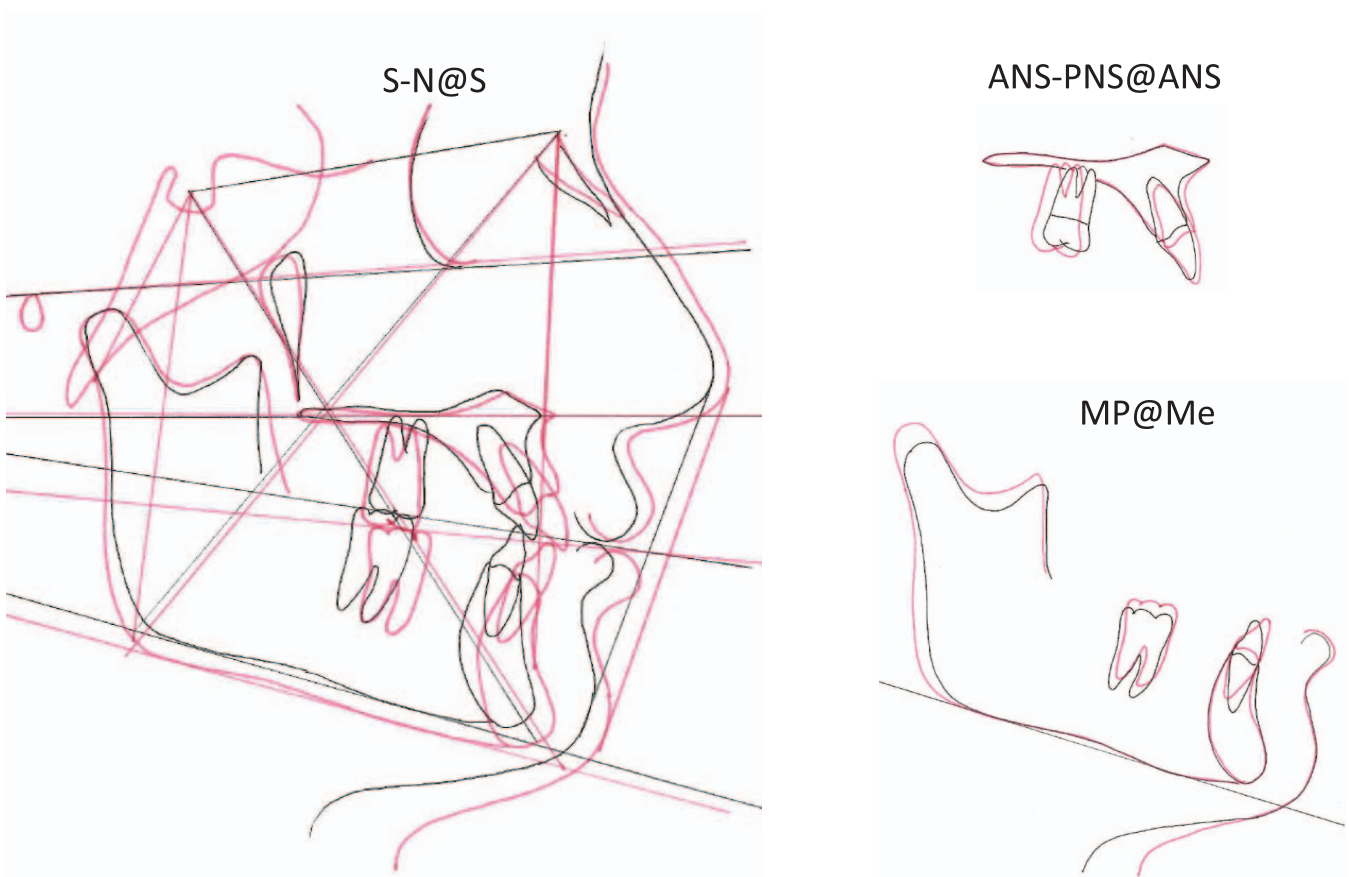


Figure 10. Cephalometric superimposition of sella-nasion plane at the point of sella (S-N@S) and palatal plane at ANS, mandibular plane at menton (MP@Me), pretreatment (black) and posttreatment (red) tracing.

second premolar and first molar teeth and was stable throughout treatment. Generally, the stability of miniscrews depends on the thickness and density of cortical bone, miniscrew design, insertion technique and angle, distance to the roots of adjacent teeth, oral hygiene, the amount of force applied, and ultimately, the clinicians' experi-

ence.¹²⁻¹⁸ The insertion of a miniscrew between the second premolar and first molar was favorable on the basis of the employed biomechanics and the 1.45 ± 0.25 mm of cortical bone thickness present in this area.^{19,20}

The distance between the roots of the adjacent teeth and the width of the attached gingiva often limit

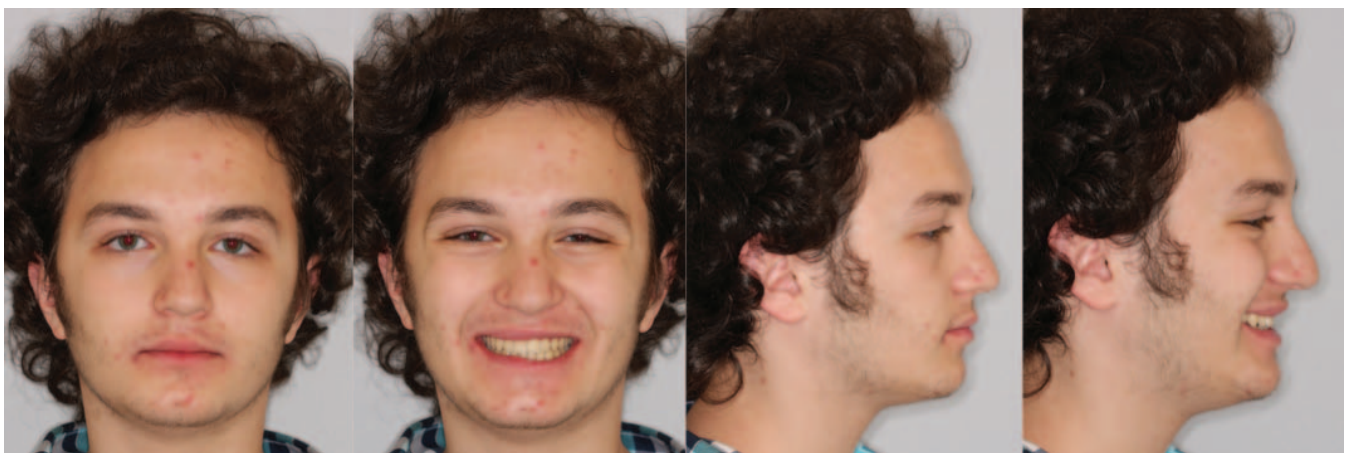

Figure 11. Extraoral photographs 2 years after orthodontic treatment.

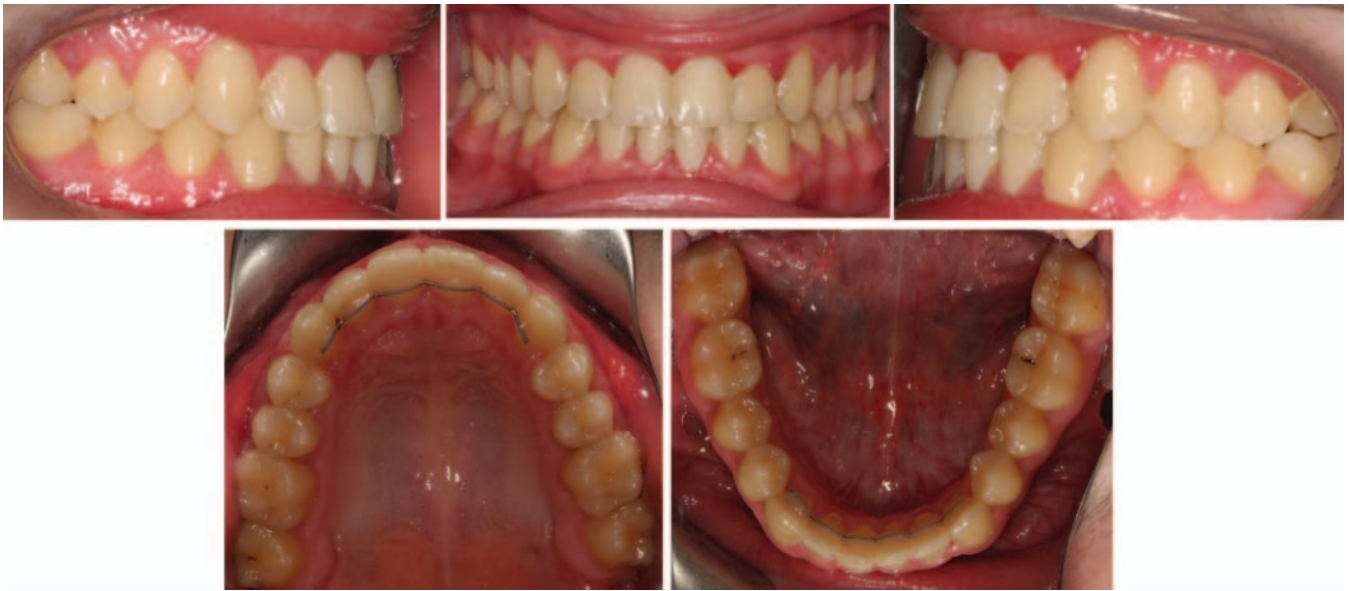

Figure 12. Intraoral photographs 2 years after orthodontic treatment.

the diameter of the miniscrew. In previous studies, a 1.6-mm maximum diameter miniscrew has been recommended.^{21–23} It has also been stated that the length, which can be as long as 6–8 mm, is not as important as the diameter.

In the present case, a force of approximately 150 g was applied for distalizing the first molar, while the optimum force previously suggested has ranged from 100 to 240 g. The need to distalize

the first and second molars required this level of force.^{24–29}

The miniscrew was used as an indirect anchorage unit. This helped not only to prevent higher forces from acting on the miniscrew but to avoid the intrusion. The load on compact bone, which is near or around the miniscrew used for direct anchorage, is higher than the load created around an indirect anchorage unit. The greater the number of support-

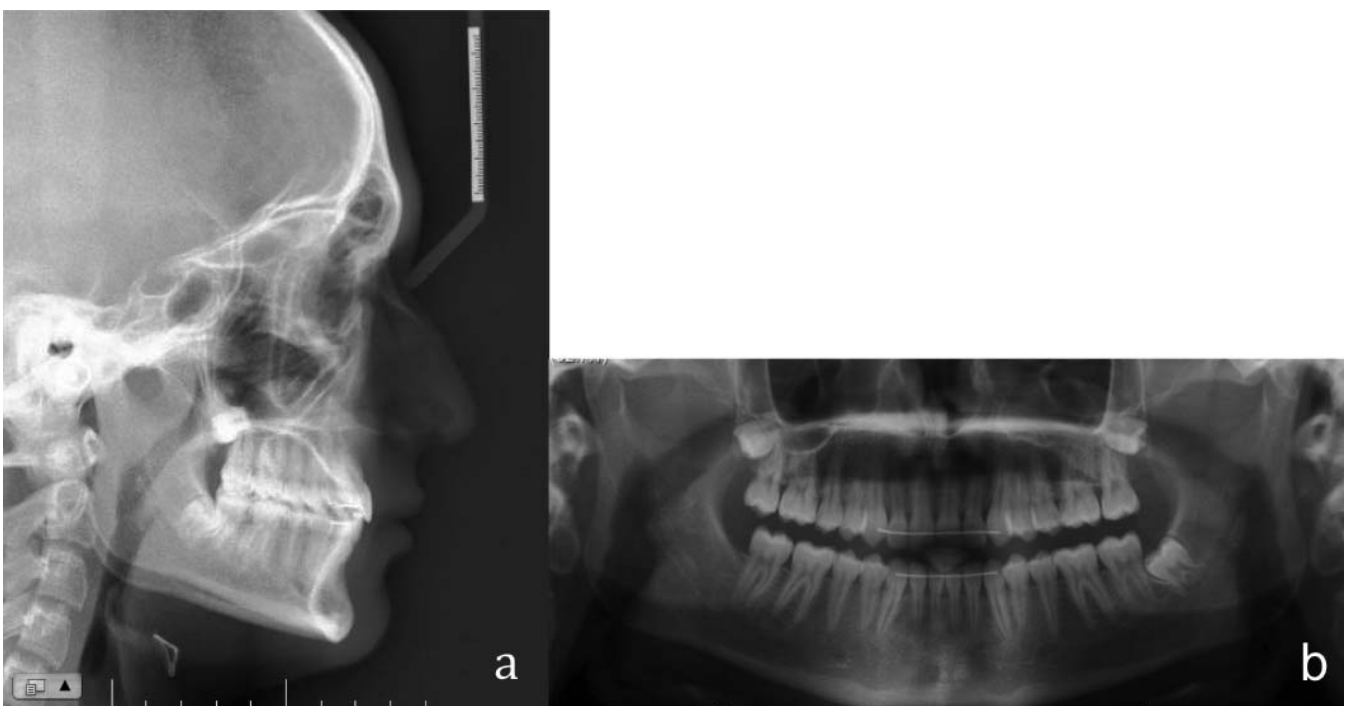


Figure 13. Panoramic x-ray, lateral cephalometric x-ray 2 years after orthodontic treatment.

ing teeth that are tied to the miniscrew under indirect anchorage, the less is the load applied to the bone surrounding of miniscrew.

In the present case, the preference was to distalize the first molar and then the premolars in a 2-step process, which achieved a total distalization of 4.7 mm. This approach saved the miniscrew from additional load and limited the possibility of early loss. The distalization of the arch can be done as an entire segment in 1 step or can be done in 2 steps involving molar distalization first, followed by premolar distalization. Since the present case had a normal vertical growth pattern, parallel movement of the distalized teeth did not have an adverse effect on the vertical dimension.

The amount of distalization in the present case was similar to that reported by others. The distalization distance indicated by Saito *et al.*³¹ was 1.8 to 10.7 mm in an animal study. Sugawara *et al.*,³² suggested that the average amount of distalization of the mandibular first molars was 3.5 mm at the crown level and 1.8 mm at the root level, with 0.3 mm mean relapse. In a recent case report, the mandibular dentition was distalized 5 mm and 2 mm on the left and right sides, respectively.³³

A nonextraction and miniscrew anchorage approach for the distalization did not adversely affect the cephalometric findings in the vertical and sagittal skeletal planes. The differences between pretreatment and posttreatment measurements were in accordance with previous studies and were maintained successfully at 2 year review.^{34,35}

REFERENCES

1. Angle EH. Classification of malocclusion. *Dental Cosmos*. 1899;41:248–264.
2. Rönnerman A. The effect of early loss of primary molars on tooth eruption and space conditions. A longitudinal study. *Acta Odontol Scand*. 1977;35:229–239.
3. Nomoto S, Matsunaga S, Ide Y, Abe S, Takahashi T, *et al*. Stress distribution in maxillary alveolar ridge according to finite element analysis using micro-CT. *Bull Tokyo Dent Coll*. 2006;47:149–156.
4. Cattaneo PM, Dalstra M, Melsen B. The transfer of occlusal forces through the maxillary molars: a finite element study. *Am J Orthod Dentofacial Orthop*. 2003;123:367–373.
5. Banmird S, Molthen R, Korn EL. Mandibular plane changes during maxillary retraction. *Am J Orthod*. 1978;74:32.
6. Sung JH, Kyung HM, Bae SM, Park HS, Kwon OW, McNamara JA. *Surgical Procedures for Microimplant Placement. Microimplants in Orthodontics*. Daegu, Korea: Dentos; 2006;39–61.
7. Burstone C. Diagnosis and treatment planning of patients with asymmetries. *Semin Orthod*. 1998;4:153–164.
8. Isik F, Sayınsu K, Nalbantgil D, Arun T. A comparative study of dental arch widths: extraction and non-extraction treatment. *Eur J Orthod*. 2005;27:585–589.
9. McNamara JA, Bookstein FL, Shaughnessy TG. Skeletal and dental adaptations following functional regulator therapy. *Am J Orthod*. 1985;88:91–110.
10. Gianelly AA, Bednar J, Dietz VS. Japanese NiTi coils used to move molars distally. *Am J Orthod Dentofacial Orthop*. 1991;99:564–566.
11. Janson G, Sathler R, Fernandes TM, Branco NC, Freitas MR. Correction of Class II malocclusion with Class II elastics: a systematic review. *Am J Orthod Dentofacial Orthop*. 2013;143:383–392.
12. Samrit V, Kharbada OP, Duggal R, Seith A, Malhotra V. Bone density and miniscrew stability in orthodontic patients. *Aust Orthod J*. 2012;28:204–212.
13. Lee J, Kim JY, Choi YJ, Kim KH, Chung CJ. Effects of placement angle and direction of orthopedic force application on the stability of orthodontic miniscrews. *Angle Orthod*. 2013;83:667–673.
14. Duaibis R, Kusnoto B, Natarajan R, Zhao L, Evans C. Factors affecting stresses in cortical bone around miniscrew implants: a three-dimensional finite element study. *Angle Orthod*. 2012;82:875–880.
15. Migliorati M, Benedicenti S, Signori A, Drago S, Barberis F, *et al*. Miniscrew design and bone characteristics: an experimental study of primary stability. *Am J Orthod Dentofacial Orthop*. 2012;142:228–234.
16. Singh S, Mogra S, Shetty VS, Shetty S, Philip P. Three-dimensional finite element analysis of strength, stability, and stress distribution in orthodontic anchorage: a conical, self-drilling miniscrew implant system. *Am J Orthod Dentofacial Orthop*. 2012;141:327–336.
17. Shah AH, Behrents RG, Kim KB, Kyung HM, Buschang PH. Effects of screw and host factors on insertion torque and pullout strength. *Angle Orthod*. 2012;82:603–610.
18. McManus MM, Qian F, Grosland NM, Marshall SD, Southard TE. Effect of miniscrew placement torque on resistance to miniscrew movement under load. *Am J Orthod Dentofacial Orthop*. 2011;140:e93–98.
19. Ono A, Motoyoshi M, Shimizu N. Cortical bone thickness in the buccal posterior region for orthodontic mini-implants. *Int J Oral Maxillofac Surg*. 2008;37:334–340.
20. Ozdemir F, Tozlu M, Germec-Cakan D. Cortical bone thickness of the alveolar process measured with cone-beam computed tomography in patients with different facial types. *Am J Orthod Dentofacial Orthop*. 2013;143:190–196.
21. Poggio PM, Incorvati C, Velo S, Carano A. Safe zones: a guide for miniscrew positioning in the maxillary and mandibular arch. *Angle Orthod*. 2006;76:191–197.
22. Schnelle MA, Beck FM, Jaynes RM, Huja SS. A radiographic evaluation of the availability of bone for placement of miniscrews. *Angle Orthod*. 2004;74:832–837.

23. Costa A, Pasta G, Bergamaschi G. Intraoral hard and soft tissue depths for temporary anchorage devices. *Semin Orthod.* 2005;111:10–15.
24. Sayinsu K, Isik F, Allaf F, Arun T. Unilateral molar distalization with a modified slider. *Eur J Orthod.* 2006;28:361–365.
25. Blechman AM, Smiley H. Magnetic force in orthodontics. *Am J Orthod.* 1978;74:435–443.
26. Cetlin NM, Ten Hoeve A. Nonextraction treatment. *J Clin Orthod.* 1983;17:396–413.
27. Gianelly AA, Vaitas AS, Thomas WM, Berger DG. Distalization of molars with repelling magnets. *J Clin Orthod.* 1988;22:40–44.
28. Bondemark L, Kurol J. Distalization of maxillary first and second molars simultaneously with repelling magnets. *Eur J Orthod.* 1992;14:264–272.
29. Bolla E, Muratore F, Carano A, Bowman SJ. Evaluation of maxillary molar distalization with the distal jet: a comparison with other contemporary methods. *Angle Orthod.* 2002;72:481–494.
30. Holberg C, Winterhalder P, Holberg N, Rudzki-Janson I, Wichelhaus A. Direct versus indirect loading of orthodontic miniscrew implants-an FEM analysis. *Clin Oral Investig.* 2013;17:1821–1827.
31. Saito S, Sugimoto N, Morohashi T, Ozeki M, Kurabayashi H, et al. Endosseous titanium implants as anchors for mesiodistal tooth movement in the beagle dog. *Am J Orthod Dentofacial Orthop.* 2000;118:601–607.
32. Sugawara J, Daimaruya T, Umemori M, Nagasaka H, Takahashi I, et al. Distal movement of mandibular molars in adult patients with the skeletal anchorage system. *Am J Orthod Dentofacial Orthop.* 2004;125:130–138.
33. Chung KR, Kim SH, Kook YA. C-orthodontic microimplant for distalization of mandibular dentition in Class III correction. *Angle Orthod.* 2005;75:119–128.
34. Kyung SH, Lee JY, Shin JW, Hong C, Dietz V, Gianelly AA. Distalization of the entire maxillary arch in an adult. *Am J Orthod Dentofacial Orthop.* 2009;135:123–132.
35. Upadhyay M, Yadav S, Nagaraj K, Nanda R. Dentoskeletal and soft tissue effects of mini-implants in Class II division 1 patients. *Angle Orthod.* 2009;79:240–247.